



PATIENT

Merlin Tarney

SPECIES

Feline

BREED

Sphynx

SEX

Male Neutered

AGE

8 years

WEIGHT

10.4lbs

INTERPRETED BY

Maggie Machen Lamy,
DVM, DACVIM
(Cardiology)

IMAGING PERFORMED BY

Dr. Belan, DVM

HOSPITAL NAME

South Pointe Vet
Clinic

REFERRING VET

Dr. Blaise

INVOICE

24171

DATE

5/12/22

PRESENTING CLINICAL SIGNS

History: Assess for heart disease, scan done on sibling revealed early HCM. Persistent cough last 14 days.

-Chest x rays: Radiopaque nodules in left lobe and caudal right lobe.

ECHOCARDIOGRAM FINDINGS

2D, m-mode, color flow and doppler imaging is available. The left ventricular wall is asymmetric with mild septal thickening. There is a diffusely hyperechoic endocardium consistent with fibrosis. Mild symmetric papillary muscle hypertrophy and remodeling. The right ventricle is subjectively normal in size and morphology. There is no left atrial enlargement present. No right atrial enlargement present. Normal RVOT velocity. No TR. Normal LVOT velocity. There is no obvious systolic anterior motion (SAM) of the mitral valve present. No MR. There is no pericardial effusion noted. No pleural effusion appreciated. No obvious cardiac tumors.

CARDIAC CHART

| FELINE CARDIAC PARAMETERS | BODY WEIGHT (kg) | HR (BPM) | IVSd (cm) (Moise, Pipers) | LVIDd (cm) (Moise, Pipers) | LVWd (cm) (Moise, Pipers) | FS (%) | EF (%) |
|---------------------------|------------------|---------------------------------|--|----------------------------|---------------------------|----------------|-------------|
| NORMAL PARAMETER | ----- | 150-240 | 0.35-0.55 | <2 (mean 1.5) | 3.5-0.55 | 35-67 | 80-100 |
| PATIENT | 4.7 | 197 | 0.64 | 1.4 | 0.48 | 47 | 82 |
| FELINE CARDIAC PARAMETERS | LA/AO (Boon) | LA/AO HEART BASE (Swe) (Abbott) | LA 2D short axis Base view (cm) (Abbott) | | LVOT VEL (m/s) | RVOT VEL (m/s) | E max (m/s) |
| NORMAL | <1.5 | <1.3 | <1.2 | | <1.6 | <1.3 | <0.9 |
| PATIENT | 1.3 | 1.4 | 1.3 | | 1.0 | 1.0 | NM |

**Note: All measurements based upon multi-modal images and methods. An average value is reported.*
Adapted from June Boon, Veterinary Echocardiography, 1998
Abbott J & MacLean H JVIM 2006;20: 111-119, Moise et al. Am J Vet Res 47:1476, 1986. Pipers et al. Am J Vet Res 40:882, 1979.

INTERPRETATION OF THE FINDINGS & FURTHER RECOMMENDATIONS

Hypertrophic cardiomyopathy (HCM) is a rule out diagnosis once a patient is deemed normotensive and euthyroid. Both should be ruled out in this case as contributing factors. The degree of disease is mild, with only focal septal thickening and no LA dilation. This would indicate the risk for clinical issues is low at this time. No additional issues are identified.

No medications are indicated prior to significant atrial dilation. It is important to note that no medications have been shown to definitively alter long term outcome at this stage, particularly in the absence of SAM.

Even with mild changes seen here, this is unlikely to be related to the reported cough. Further respiratory evaluation/treatment is recommended.

Monitor at home for any respiratory issues or signs of blood clot events (neurologic change, paralysis, etc.). Anesthetic risk is considered mild, however judicious fluid administration is advised if needed with careful RR/RE monitoring to screen for fluid overload. Additionally, drugs



PATIENT

Merlin Tarney

that stimulate heart rate should be avoided unless clinically necessary (glycopyrrolate, atropine). Risk for complication with steroid use typically follows LA dilation, which in this case is mildly elevated. If needed, monitoring of RR/RE is advised particularly in the initiation phase.

SPECIES

Feline

PLAN

A screening blood pressure and T4 are recommended, then every 6 months lifelong.

BREED

Sphynx

A recheck echocardiogram is recommended in 6 months to assess for progression, sooner if any issues arise in the interim.

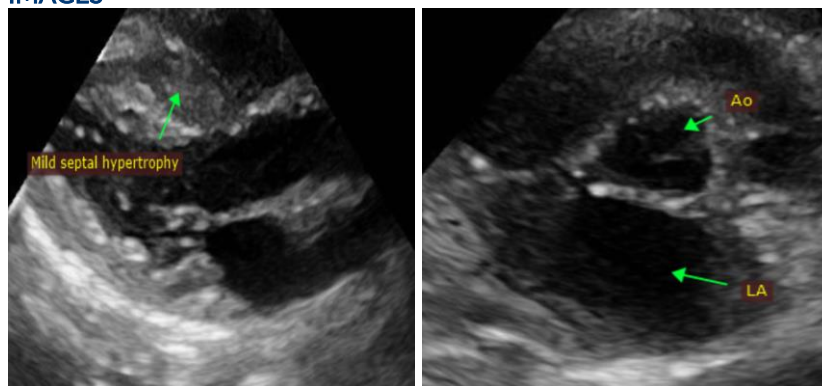
SEX

Male Neutered

IMAGES

AGE

8 years



WEIGHT

10.4lbs

The information and recommendations provided are based on the images presented by the referring veterinarian. No evaluation can be communicated regarding pathology that was not visible in the image/video clips provided.

INTERPRETED BY

Maggie Machen Lamy, DVM, DACVIM (Cardiology)

Thank you for this referral. This report was generated using transcription software, and minor dictation errors may be present. If the clinical or image interpretation does not parallel your findings or if I can be of any further assistance, please contact me.

IMAGING PERFORMED BY

Dr. Belan, DVM

Maggie Machen Lamy, DVM
Diplomate of the American College of Veterinary Internal Medicine (Cardiology)
info@sonopath.com

HOSPITAL NAME

South Pointe Vet Clinic

REFERRING VET

Dr. Blaise

INVOICE

24171

DATE

5/12/22